

ASC-61

SOUTHERN REGIONAL BEEF COW/CALF HANDBOOK:
DETERMINING PREGNANCY IN CATTLE

ISSUED: 1-78

REVISED:

A.M. Sorensen, Jr. and J.R. Beverly*

This material is made available through assistance from the Kentucky Beef Cattle Association

* Professor, Department of Animal Science, and Extension animal reproduction specialist, Texas A&M University.

Economic returns from the beef cattle industry depend largely on the percent calf crop and the weaning weight of calves to be sold.

The following discussion describes a way of improving the calf crop percentage through pregnancy determination and elimination of non-pregnant cows. This determination, called palpation, is made by inserting the arm into the rectum and feeling the reproductive tract for pregnancy indications.

Equipment

Little equipment is needed in palpation. The individual doing the palpating should wear protective covering on the arm and hand. This may be a rubber sleeve or a plastic sleeve which covers the arm to the shoulder. This protection guards against disease and eliminates irritation of the arm. A lubricant, such as liquid soap, is preferred over detergent. Use a rubber band to hold the plastic sleeve on the upper arm. Dry rubber sleeves immediately after use and sprinkle with talcum to avoid deterioration. Plastic Sleeves may tear after several uses, thereby reducing protection. Do not attempt to use these later.




Figure 1. Chute arrangement for restraining cows.

The chute for holding the animal during palpation should allow the animal to stand on the ground in a normal position. It should have a front wall or gate and a bar just above the hocks in the rear, [Figure 1](#). This bar eliminates the animal's kicking and protects the palpator during manipulation of the

reproductive organs.

Include an entrance gate in the chute at the rear of the animal to allow entrance and exit for the palpator. Provide a gate which will swing across the crowding chute in front of other animals coming behind the palpator. Squeeze chutes may be used. However, the noise made as the animal enters the chute and her unnatural position sometimes excite the animal, making palpation more difficult.

Palpation alone takes only a few seconds. The speed with which pregnancy is determined depends largely on management of the livestock as they come through the chutes, stage of pregnancy and the palpator's experience. As many of 800 head of cattle can be palpated in a normal working day under ideal conditions. However, efficiency is greatly reduced if the palpator must help bring the cattle into the chute, climb over the chute wall to get behind the animal and then palpate the animal.

Palpators should practice certain precautions. The first of these concerns the palpator's safety. Restrain the animal so she cannot jump over the side of the chute or kick the palpator. Prevent other cattle from

coming up behind the palpator as he attempts to determine pregnancy.

Consider also the animal's safety. Do not place the animal's head in a stanchion or headgate. This tends to excite the animal. Replace broken boards in the chute that could injure the animal's legs. A dirt floor chute is most desirable. Animals in a chute with a slick floor may become excited and lose their footing. Cleats across the floor stabilize footing.

Reproductive System

Thorough knowledge of the female reproductive system is essential in palpation, [Figure 2](#). The female germ cell, called the *ovum* or *egg*, develops in a *follicle* on the *ovary*. The ovaries are suspended rather freely in the body cavity by *ligaments* attached to the top of the abdominal cavity. These move from one location to another in the cavity.

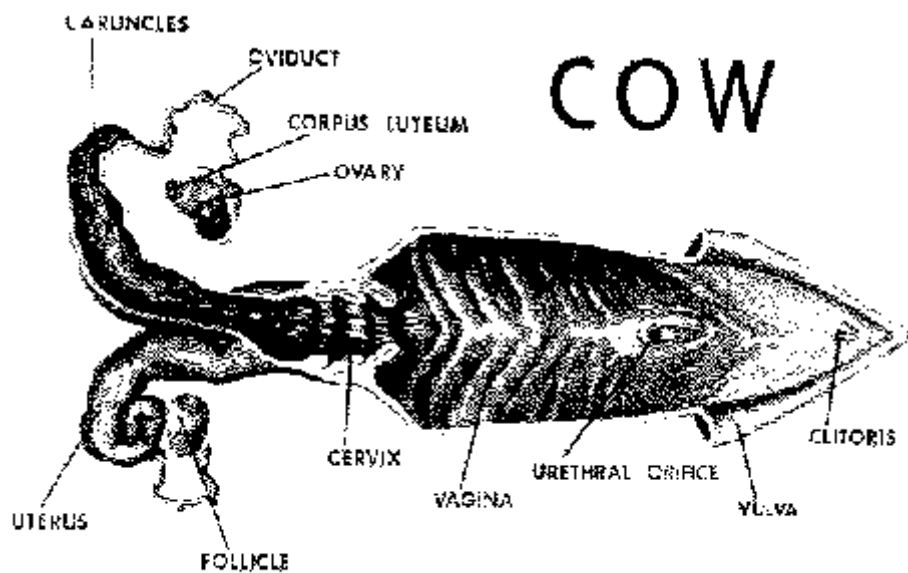


Figure 2. Anatomy of the reproductive tract

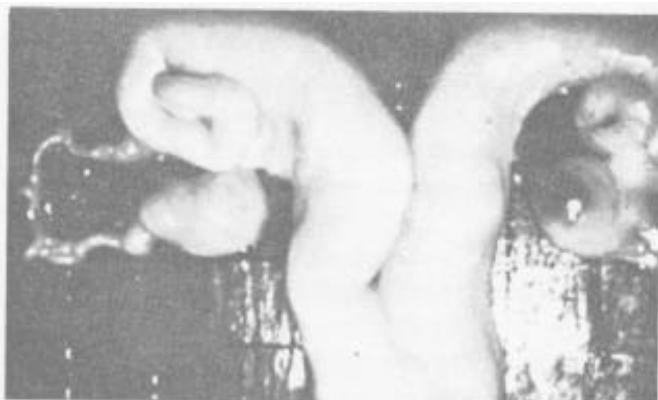The ovaries (two) are located on each side of the cavity. They are approximately 1/2-inch wide, 3/4-inch deep and 1-inch long in a normal cow. This size varies considerably, depending upon the stage of the estrous cycle.

The ovary should feel firm but not hard. The follicle which contains the egg is a blister-like projection on the surface of the ovary. It may reach a size of 1/2 to 3/4-inch in diameter and

protrude approximately 1/4-inch from the surface. The follicle has the feel of a blister or tissue filled with fluid. An experienced person can palpate the follicle on the ovary.

As the follicle ruptures releasing the egg, the cavity fills with cells to form another body, called the

corpus luteum, [Figure 3](#). (Large mature follicle on right ovary. Mature corpus luteum on left ovary.) This develops as a cellular mass and protrudes with a teat-like projection at the point of rupture. Approximately 15 days after the animal is in estrus, the corpus luteum begins to regress and almost completely disappears within the next 10 days. Another follicle is growing and will rupture approximately 21 days after the previous one. This cycle pattern is followed at approximately



ESTROUS CYCLE OF THE COW

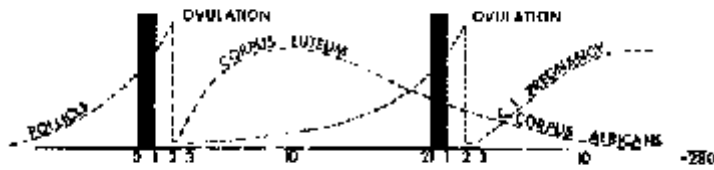


Figure 4. Note the cycle pattern is followed at approximately 21-day intervals.

21-day intervals, [Figure 4](#). The corpus luteum can also be palpated on the ovary by an experienced person. The large follicle on the ovary indicates the animal is approaching the time of estrus. A corpus luteum on the ovary indicates the animal is in about the midpoint of the estrous cycle or is pregnant. The corpus luteum persists in the cow throughout pregnancy.

Therefore, palpation of the corpus luteum may either indicate a stage in a normal cycle or pregnancy.

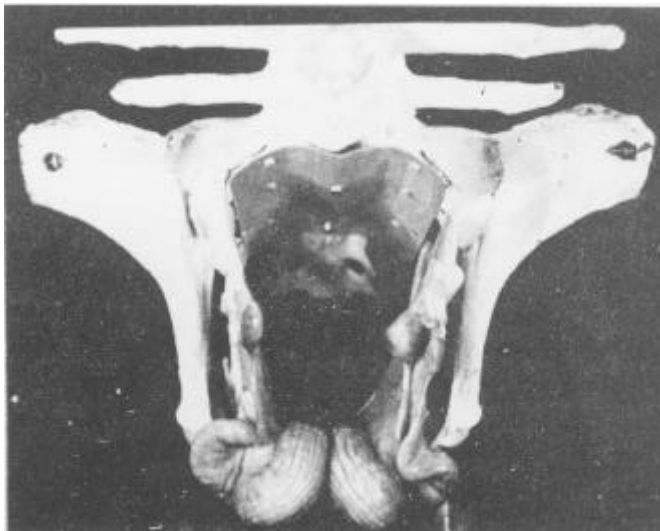

Figure 7. Reproductive tract of mature cow on the floor of pelvis.

After the egg is released from the follicle, it moves into the *oviduct*, a small tube that acts as a passageway for the egg to go from the ovary into the *uterus*. The two oviducts also act as sites of fertilization. The egg normally is fertilized about one-third of the way down the oviduct by sperm that have entered during copulation.

The egg moves into the horn of the uterus and, if fertilization has occurred, begins its cell division. The egg continues to multiply and lay down its membranes, implanting itself in one of

the uterine horns.

The cow's uterus is made up of two horns with a connecting body between, [figure 2](#). Therefore, in development of the membranes, they pass from the tip of one horn through the body to the tip of the other horn. Attachment takes place throughout. The uterus is lined with numerous raised prominences, called *caruncles*, with form attachment points for developing *cotyledons* or "buttons" on the fetal membranes. The next portion of the reproductive tract toward the exterior is called the *cervix*, [figure 2](#), and is made up of a connective tissue substance that feels much like gristle. The cervix is tortuous with folds protruding into the lumen and extending in the direction of the exterior. Within these folds are numerous glands which secrete fluid abundantly during estrus. It becomes thick and tenacious during the functioning period of the corpus luteum and during pregnancy.

The next portion of the tract, the *vagina*, [figure 2](#), acts as a receptacle for the penis during copulation and the point of deposition of the spermatozoa. The *bladder*, which opens on the floor of the vagina through the *urethral orifice*, from this point to the vagina exterior acts as a common passageway for urine and passage of young at birth.

The vagina has the feeling of a thin-walled organ similar to that of the uterus. The *vulva* is the external portion of the reproductive tract and may be seen as two prominent lips.

The entire reproductive organs of an animal vary considerably in size and feel with the stage of development during pregnancy and also with the size and reproductive history of the animal. Generally, the size of the entire nonpregnant reproductive tract is 12 to 18 inches long. In young heifers that have just reached puberty, the reproductive organs may be only 8 inches long. The reproductive tract of older cows that have had several calves may extend to 24 inches. Diameter of the uterine horns is approximately 3/4 to 1 inch and the length of the horns 6 to 8 inches with a 3 to 4-inch body. The cervix is approximately 1 to 2 inches in diameter and 3 to 5 inches long.

Developmental Stages

Periods of development in a young calf's life are divided into three parts. The period of the *ovum* is that time from fertilization until the egg has divided enough times to take on a particular form. This occurs about the thirtieth day when there is an enfolding of the layers of the developing egg. At this stage, the newly developing animal is called an *embryo*. The period of embryonic development lasts until attachment of the fetal membranes to the lining of the uterus - approximately 38 days. During the embryonic stage, various organs and systems are laid down. These include the respiratory system, nervous system, digestive system, circulatory system and reproductive system.

The embryo, as it develops, floats freely in the uterine cavity, bathed by a secretion called uterine milk.

During this time, the embryo lays down all of the organs and tissues.

When the embryo is about 38 days old, the *fetus* period begins. This term is used until the newborn is expelled at parturition. During the fetus stage, continued attachment takes place at the numerous caruncles lining the uterus. These attachments provide transfer of nutrients and waste materials for the developing fetus. Parturition occurs approximately 280 days after fertilization, [Figure 6](#).

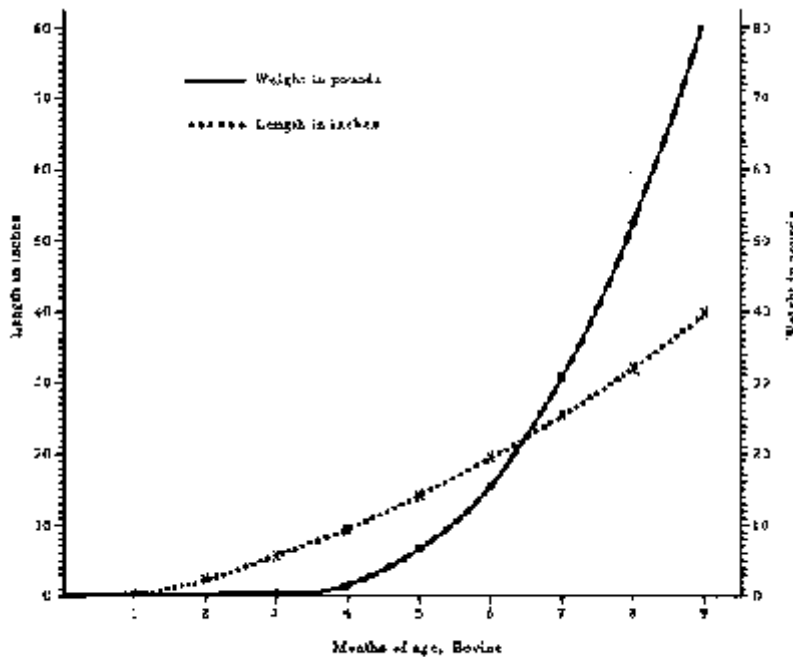


Figure 6. Growth of fetus. Parturition occurs approximately 280 days after fertilization.

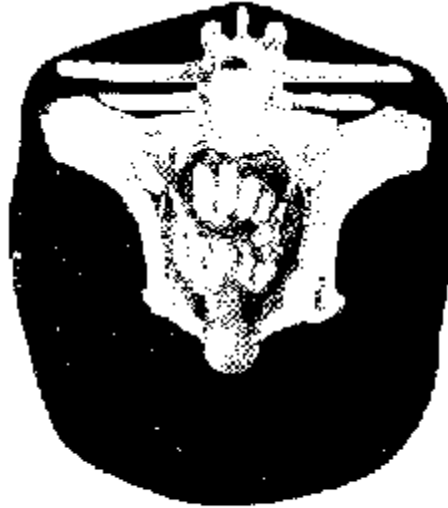

Figure 5. Reproductive system of young cow, viewed from inside of animal.

Palpation

Either hand may be used in palpation. One hand may grasp the cow's tail as a handle. The other hand should be well lubricated and shaped into a wedge by bringing the fingers together as closely as possible. The hand is pushed through the anus into the rectum with one swift thrust. As the hand enters the rectum, fold the fingers into a modified fist, [Figure 5](#). By bailing the hand into a modified fist as it enters the rectum, the fecal material is pushed aside and the rectum straightened. Folds in the

rectum do not straighten as easily if the fingers are held in a pointed position. This also eliminates puncturing of the rectal wall with the sharper pointed fingers. However, puncturing is rare, as the rectum is thick-walled and resistant.

Cleaning the cow's rectum of fecal material usually is not necessary. However, in early stages of learning, cleaning the rectum increases feel. Remove fecal material of cattle on range since it is so dry. Feeling through the rectal wall is similar to feeling through a layer or two of thin rubber. Most cattle are cooperative. Thus, it should be possible to feel the paunch and pick-up the reproductive organs without difficulty.

Usually, the longer the examination, the more resistance encountered. Occasionally, a small amount of bleeding occurs. This should not upset the palpator. An indication of rectum damage is a sandpaper or gritty feeling. In this case, the mucosa lining the rectum has been rubbed off in the palpation process. It is best to stop further palpation when this occurs.

A thrust of the arm to the elbow is usually much better than trying to put the hand into the rectum and gradually working forward. It is much easier to work to the rear, since that is the direction the cow is pushing the fecal matter and the inserted arm. In palpating, assume the animals are pregnant. Therefore, reach farther than wrist deep to pick up the uterus and the calf within.

Certain landmarks are evident inside the cow. The *pelvis* forms a bone cradle for the reproductive system, [Figure 5](#). The nonpregnant tract usually is located near the top of the pelvic cradle and felt easily with downward pressure. As pregnancy advances, the uterus and cervix move down and into the body cavity.

The *cervix* with its firm feel is also a good landmark, [figure 2](#). After the locating the cervix, the palpator can move forward to the uterus to determine pregnancy.

The paunch, located directly forward and to the left, may feel like the end of a football and be rather soft and mushy. The feel depends on the amount of feed in the paunch. The feedstuff when mashed slowly returns to normal shape. It *does not* have the watery, soft feel of the pregnant uterus.




Figure 8. Separation of horns on the uterus.

The "open" reproductive tract normally lies on the floor of the pelvis. The horns of the uterus are coiled on the front edge of the pelvis or, in older cows, may hang slightly into the abdominal cavity. The entire tract may be held in the hand at this stage. Slight pressure by the middle finger will separate the horns of the uterus, [Figure 8](#). The ovaries are located in the broad ligament on each side.

30-day pregnancy. A palpator, with skill and practice, can detect pregnancy as early as 30 days after breeding. Palpation at this early stage should be accompanied by good breeding herd records. The palpator through these records knows the approximate breeding date of the animal.

In the early stage of pregnancy, the uterus, filled with a small amount of fluid, will feel slightly thinner. One horn is enlarged a little more than the other. Presence of the embryonic vesicle at this time is determined by running the horn between the fingers in a milking action to feel the vesicle pop through the fingers, [Figure 9](#).

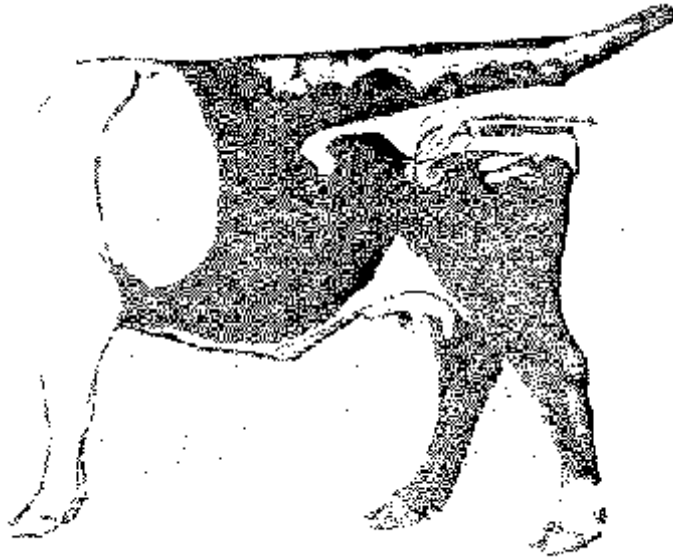


Figure 9. Position of hand in early pregnancy.

The embryo is only about 1/2-inch long. However, the vesicle surrounding it is approximately 3/4-inch in diameter and filled with fluid, such as a balloon filled tightly with water. On the same side as the enlargement, the palpator will find a corpus luteum on the ovary. The uterus, in much the same location as a nonpregnant uterus, has not been displaced because of size or weight at this time. The outer embryonic vesicle, which is rather thin with little fluid, may be 18 to 24 inches long. By pinching the horn of the uterus carefully, the membranes of this vesicle are felt as they slip between the fingers.

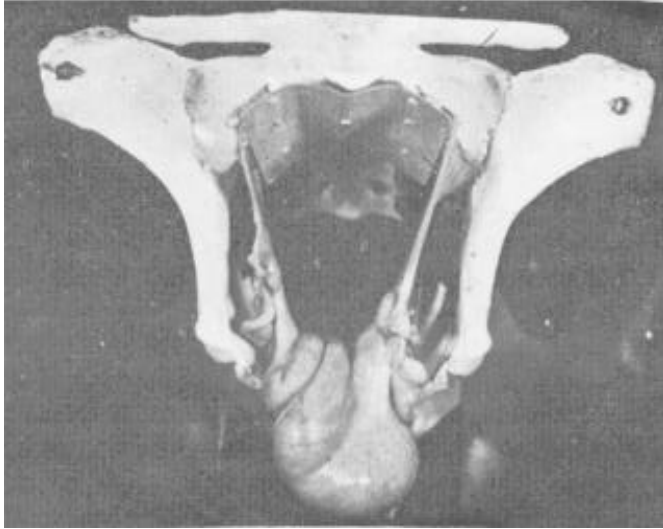

Figure 10. 60-day pregnancy. Uterus hangs over pelvic brim.

45-day pregnancy. Most palpators prefer bulls be separated from cows at least 45 days before pregnancy determination. At 45 days, one horn of the uterus containing the fetus is somewhat enlarged and thinner walled and the corpus luteum is on the ovary of the same side. The fetus at this stage is approximately 1 inch long. The vesicle around it is somewhat egg-shaped and measures approximately 1 to 1 1/2 inches long. The outer membrane, which contains considerable fluid, may be felt through the uterine wall. Attachment of the membranes

to the uterus has just taken place at approximately 38 to 40 days. Therefore, avoid moving the fetus about in the uterus. The caruncles on the uterus join the cotyledons on the fetal membranes for nutrient exchange.

60-day pregnancy. The uterus has enlarged until one horn is about the size of a banana, measuring 8 to 10 inches long. Weight of the contents pulls the uterus into the body cavity just over the pelvic brim, Figure 10. The fetus has grown rapidly and, at this stage, is about 2 1/2 inches long. The embryonic vesicles are still prominent and, at this stage, may be felt without feeling the fetus.

The uterine walls have thinned considerably. The best method of feeling the fetus is to bobble it with your hand so that by gently tapping the uterus the fetus swings as a pendulum and hits against the wall of the uterus and vesicle. The cervix remains on top of the pelvic cradle with the uterine horns moving forward and downward over the brim. The ovaries are still suspended by the broad ligaments and in early stages will be rather high in relation to the uterus. As before, a corpus luteum should be on the ovary of the same side as the developing fetus. The presence of the fetus eliminates a need for feeling other structures.

90-day pregnancy. The uterus will have enlarged considerably by this time, filled with fluid and increased, growth of the fetus, [Figure 11](#). The fetus now is about 6 1/2 inches long and has displaced

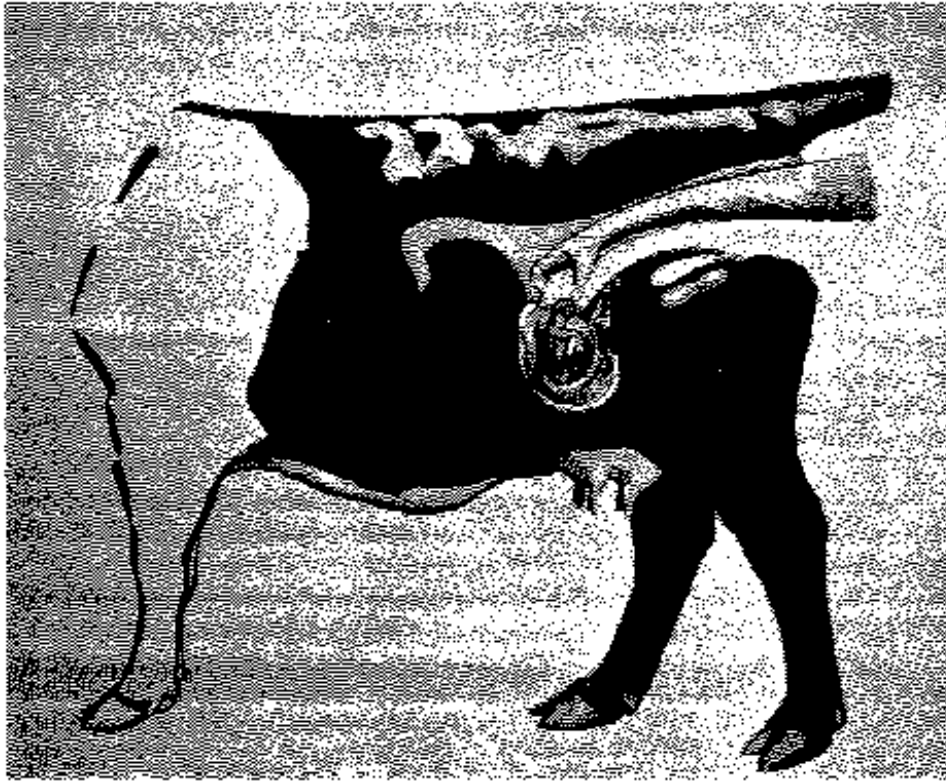


Figure 11. Position of 90-day fetus. The fetus is now about 6½ inches long and has displaced itself to the floor of the abdominal cavity.

itself to the floor of the abdominal cavity, indicating the uterus has stretched considerably. The cervix may be pulled to the pelvic brim so that the cervix, body and horns of the uterus are in the abdominal cavity. The ovaries are usually pulled down with the uterus to much lower than normal and may be palpated to either side of the uterus. In larger animals, this is a difficult stage of pregnancy because of displacement and the distance from the anus to the developing fetus.

Factors other than

presence of the fetus itself may have to be considered at this stage. Displacement of the uterus, an indication of pregnancy, should be considered. Another indication of pregnancy is enlargement of the uterine artery with its characteristic "whirring" pulsation. This artery passes in the forward fold of the broad ligament supporting the uterus. At 3 months, it is approximately 1/8 to 3/16 inch in diameter. The pulse of the heart beat is felt easily as blood is carried into the uterus to nourish the developing fetus. Do not confuse the uterine artery with the femoral artery lying on the inside of the thigh which supplies the hind legs. The femoral artery is lying in the muscle but may be palpated. Remember that the uterine artery is in the broad ligament and may be moved 4 to 6 inches, whereas the femoral may not. Another pregnancy indication is presence of a corpus luteum on one of the ovaries, although this corpus luteum may appear here even in a normal cycle. The best indication of pregnancy in absence of the fetus is the presence of cotyledons. Cotyledons in a 3-month pregnancy should be flattened and egg-shape and measure 3/4 to 1-inch across. Although rather soft to the touch, they are firmer than the thin-walled uterus. The membranes still are filled tightly with fluid, [Figure 12](#).

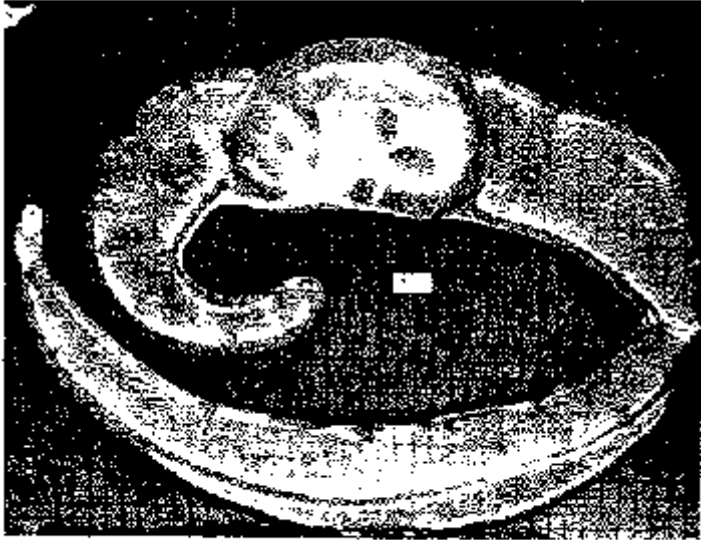


Figure 12. 79-day fetus, with surrounding membranes filled tightly with fluid. Crown width 1/4 inch.

120-day pregnancy. At this stage, the fetus is displaced similarly to the 90-day fetus. However, it has enlarged to approximately 10 to 12 inches long. The head is about the size of a lemon. Often the head

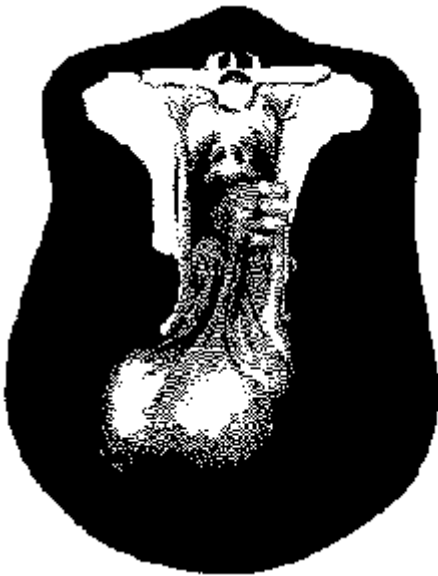


Figure 13. 4-month pregnancy. Tract lies on floor of abdominal cavity. Palpation of uterine artery.

of the developing fetus is picked up before any other part. The enlarged fetus fills a greater portion of the abdominal cavity and is easier to feel than the 3-month fetus, [Figure 13](#). All other

characteristics have changed some. Presence of the cotyledons is more noticeable, since they have developed to approximately 1 1/2 inches in length. The pulsating uterine artery may be palpated, as well as the corpus luteum and displacement of the entire reproductive tract.

Over 5-month pregnancy. The main change until parturition will be in size, [Figure 14](#), as the fetus enlarges rapidly utilizing more of the abdominal cavity. Table 1 summarizes outstanding identifying characteristics.

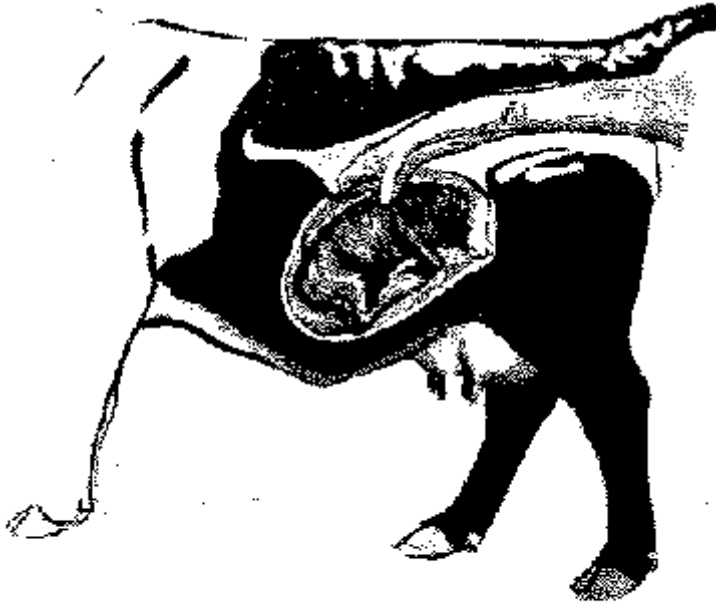


Figure 14. 5-month pregnancy. Enlarged calf now fills abdominal cavity.

Other Factors

The paunch.As one reaches into the rectum, feeling directly forward and to the left, the dorsal posterior sac of the paunch may be palpated. This paunch in an animal on good pasture or on full feed will be rather firm and plastic to the touch. By mashing the paunch you notice an indentation which gradually smooths back over indicating that the paunch is full of feedstuff. This dorsal posterior sac may feel much like the end of a football, coming to somewhat of a point. This may be misinterpreted under careless examination as a large uterus in latter stages of pregnancy.

TABLE 1. FETAL SIZE AND CHARACTERISTICS USED IN DETERMINING PREGNANCY

Days of Gestation	Fetal Size		Identifying Characteristics
	Weight	Length (Inches)	
30	1/100 oz.	2/5	One uterine horn slightly enlarged and thin; embryonic vesicle size of large marble. Uterus in approximate position of nonpregnant uterus. Fetal membranes may be slipped between fingers from 30 to 90 days.

45	1/8-1/4 oz.	1-1 1/4	Uterine horn somewhat enlarged, thinner walled and prominent. Embryonic vesicle size of hen's egg.
60	1/4-1/2 oz	2 1/2	Uterine horn size of banana; fluid filled and pulled over pelvic brim into body cavity. Fetus size of mouse.
90	3-6 oz.	5-6	Both uterine horns swollen (3 to 3 " in diameter) and pulled deeply into body cavity (difficult to palpate). Fetus is size of rat. Uterine artery 1/8 to 3/16" in diameter. Cotyledons 3/4 to 1" across.
120	1-2 lb.	10-12	Similar to 90-day but fetus more easily palpated. Fetus is size of small cat with head the size of a lemon. Uterine artery 1/4" in diameter. Cotyledons more noticeable and 1 1/2 inches in length. Horns are 4 to 6" in diameter.
150	4-6 lb.	12-16	Difficult to palpate fetus. Uterine horns are deep in body cavity with fetus size of large cat--horns 6-8" in diameter. Uterine artery 1/4-3/8 in diameter. Cotyledons 2 to 2" in diameter.
180	10-16 lb.	20-24	Horns with fetus still out of reach. Fetus size of small dog. Uterine artery 3/8-1/2" in diameter. Cotyledons more enlarged. From sixth month until calving a movement of fetus may be elicited by grasping the feet, legs or nose.
210	20-30 lb.	24-32	From 7 months until parturition fetus may be felt. Age is largely determined by increase in fetal size. The uterine artery continues to increase in size--210 days, 1/2" in diameter, 240 days.to 5/8" in diameter; 270 days, 1/2 to 3/4" in diameter.
240	40-60 lb.	28-36	
270	60-100 lb.	28-38	

Cotyledons. Cotyledons may be interpreted as ovaries or vice versa. Cotyledons do not have the solid feel of an ovary but are rather soft. The best comparison is to that of dried apricots soaked in water. The ovaries are more rounded and egg-shaped with a firm feel. Only two are present.

Pyometra. In this condition, the uterus is filled with white blood cells attempting to clear up disease organisms. The uterus may be fluid to the touch or may be somewhat solidified, feeling rather plastic. This stage may be confused with early pregnancy stages if the uterus is in a fluid condition and only partly filled. In the latter stages of pyometra, the uterus becomes rather firm.

Large uteri. In older cows that have had many calves, the uterus may not return to its normal size as in a younger cow. The enlarged uterus may feel as if displaced over the brim of the pelvis as in a 3 to 4-month pregnancy. Careful manipulation of the uterus shows no fluid and no cotyledons developing in the open cow. Relaxation of the broad ligament tends to cause a similar condition.

Bladder. The urinary bladder may be interpreted as pregnancy in the 60 to 75-day stages. At this time, the full bladder feels similar to the uterus filled with fluid. Careful tracing should indicate a bladder, where there is only one body, or a pregnant horn of the uterus, where both horns can be palpated and traced back to the cervix.

Enlarged cervix. In some Brahman and Brahman crossbred cattle, an enlarged cervix is found that is

firm and has the feel of a developing fetus in the latter stages. Tracing the reproductive tract distinguishes between the two.

Breed differences. Brahman, Brahman crossbred, Santa Gertrudis, Charolais, Holstein and Brown Swiss cattle, because of their increased size, are slightly more difficult to palpate in certain stages of pregnancy than the smaller European breeds.

In 3 to 4-month stages, the uterus has dropped so deeply into the body cavity it is almost impossible to palpate. In such instances, pass the hand under the cervix and lift the uterus to feel the fetus itself. By lifting the uterus and quickly moving the hand down into the body cavity, the presence of the fetus is felt by bobbing the fluid and the fetus through the wall of the uterus.

Brahman and Charolais breeds appear to have more tissue inside than smaller breeds. More folds of the omentum seem to cover the intestines, making it slightly more difficult to pick up the uterus.

Charolais cattle seem to have less flexibility in the rectum. It is commonly harder to feel deep in the body cavity in these cattle, and lateral movement is somewhat restricted.

The uteri of heifers of Brahman breeding vary considerably. It is not uncommon to find 1,000-pound heifers with uteri measuring only 4 to 6 inches in length, as compared to a normal uterus which would be 10 to 12 inches.

Highly finished cattle for show or on lush pastures may be filled with fat which interferes with movement and feel. These cattle are very difficult to palpate. Repalpate at a later date in case of doubt.

Recommendations

Practice! Experience is the key to palpation. In many instances the ranch manager should not be the one to palpate but should supervise the operation and critically observe the cows. Unhealthy, unsound and undesirable types should be eliminated as well as open cows.

Shorten the calving interval by reducing the time during the breeding season when the bulls are with the cows. Cows that settle first are those most adapted to reproduction. Wait approximately 45 days after the bulls are removed to palpate. Most cows should conceive at the beginning of the season, and only a few will be short-term pregnancies.

Cull as critically as feasible. If every open, unsound cow can be removed, cull immediately.

Remember, palpation is an art and a skill. It pays dividends to the person who uses it wisely.