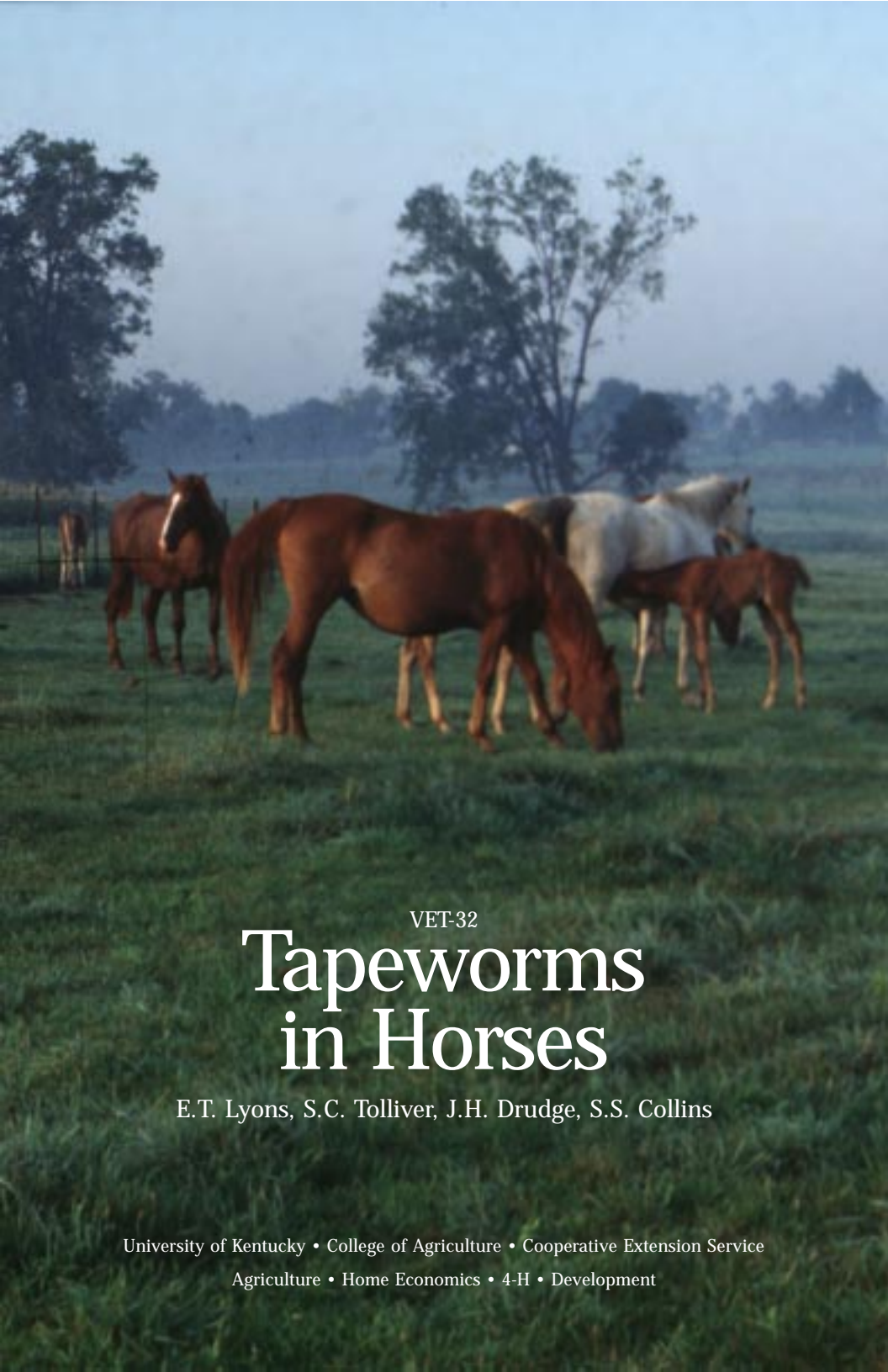

VET-32

Tapeworms in Horses

E.T. Lyons, S.C. Tolliver, J.H. Drudge, S.S. Collins

University of Kentucky • College of Agriculture • Cooperative Extension Service

Agriculture • Home Economics • 4-H • Development

Acknowledgments

Grateful appreciation is expressed to Allison Lucas Wright for designing the tapeworm life cycle and to the Burgess Publishing Company for allowing use of drawings of the three tapeworm species adapted from *Veterinary Helminthology* by Morgan and Hawkins (1949; 400 pp.).

Tapeworms in Horses

E.T. Lyons, S.C. Tolliver, J.H. Drudge, S.S. Collins

Species

Three species of tapeworms (*Anoplocephala perfoliata*, *Anoplocephala magna*, and *Paranoplocephala mamillana*) can be found in horses in the United States. Presently, the most common species is *A. perfoliata* or the cecal tapeworm. Less common are the largest species, *A. magna*, located in the posterior small intestine and the smallest species, *P. mamillana*, which lives in the anterior small intestine and occasionally the stomach.

Characteristics

Tapeworms belong to the group of parasites called flatworms or cestodes. Typically, they have a scolex or “head” and a flattened strobila or “body.” Various structural differences separate the species of tapeworms. One of the most obvious ones is the flaps or lappets found on the scolex of *A. perfoliata* (Figures 1 and 2). The scolex, equipped with four suckers, is used for attachment to the organ, usually intestine, that the tapeworm parasitizes. A strobila is composed of a ribbon of individual segments or proglottids. Each proglottid contains various body systems including reproductive. The most posterior proglottids become gravid or literally filled with eggs and then separate, passing out in feces of horses (Figure 2).

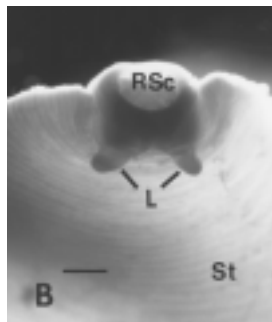
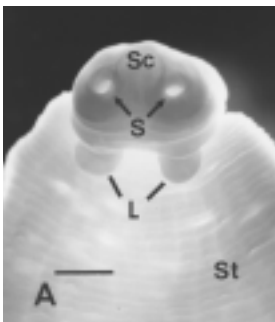
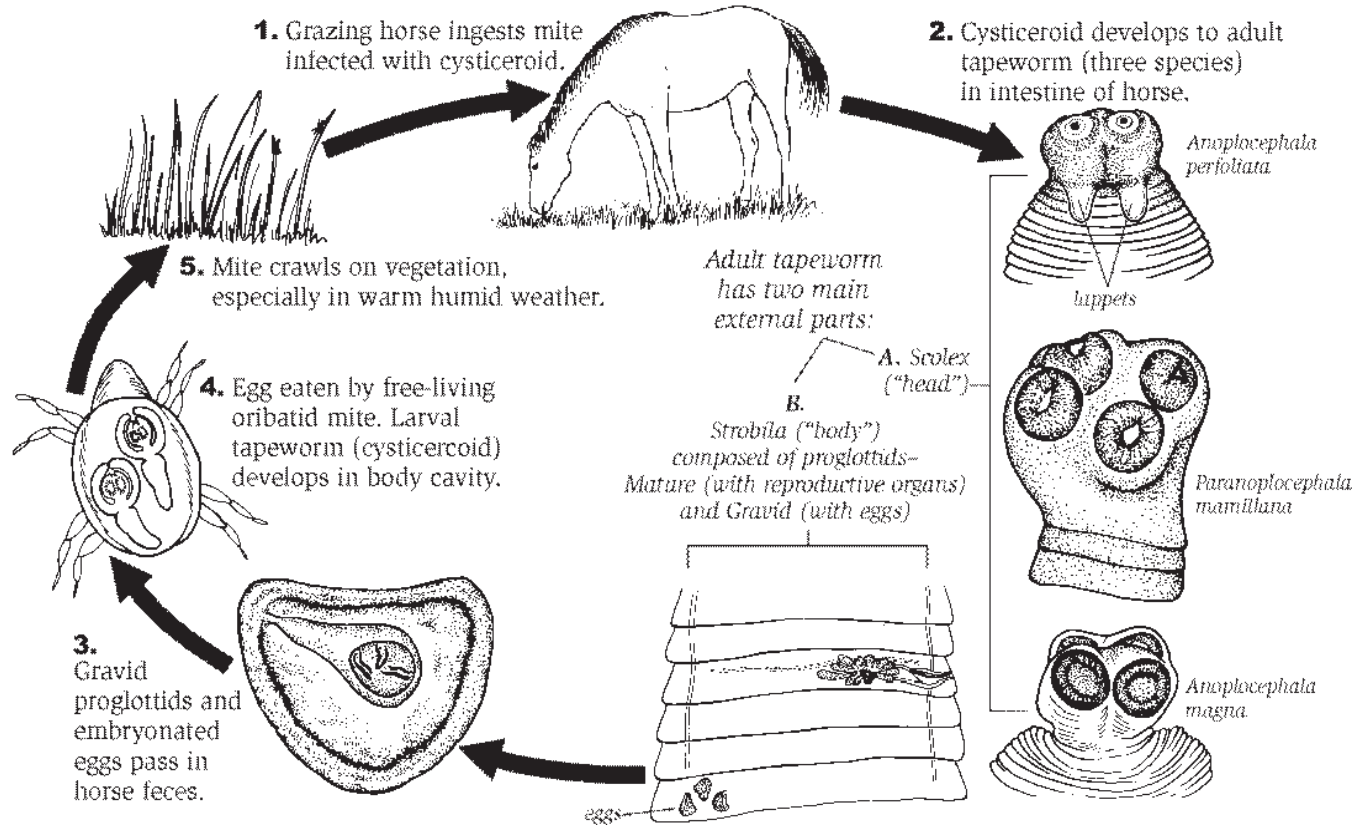


Figure 1. *Anoplocephala perfoliata*. Scolex (Sc) with two of the four suckers (S) and lappets (L) evident as is the strobila (St). Scale bars = 1.0 mm. A. Protracted scolex; B. Retracted scolex (RSc).

Figure 2. Life cycle of the three tapeworm species in horses.



Adapted from drawings by Allison Lucas Wright and the Burgess Publishing Company (used with permission).

Nutrition

Tapeworms have no mouth parts and cannot actively ingest food. Nutrients are absorbed through the walls of the proglottids.

Life Cycle

The life cycle of tapeworms includes the definitive host or horse in which they mature and an intermediate host or oribatid mite in which immature stages are found (Figure 2). Horses, as they graze or eat other feed, accidentally ingest oribatid mites infected with immature or cysticercoïd stages. Inside the horse, cysticercoïds develop to adult tapeworms in about two months. Tapeworm eggs within gravid proglottids, or free, pass in horse feces and are eaten by free-living soil or oribatid mites. Within the mites, cysticercoïd stages develop in two to four months. Infected mites are then eaten by horses and the tapeworm cycle continues.

Prevalence

More than 50 percent of Thoroughbreds examined in central Kentucky the last several years were infected with *A. perfoliata*. There does not appear to be an acquired or age resistance to this parasite in horses because all ages, including older ones, can be infected.

Diagnosis

Diagnosis of infections of tapeworms in live horses is difficult. Detection of their eggs in horse feces is not reliable by standard techniques for determining presence of eggs of other internal parasites, such as nematodes. Therefore, not finding tapeworm eggs in feces does not mean these parasites are actually absent in a horse. Tapeworm eggs are angular and vary in appearance, depending on the view presented. The eggs have hyaline-like thickened walls and contain an embryo with six hooklets (hexacanth). Tapeworm infections can sometimes be verified by finding specimens in feces after a horse has been treated with a drug active against these parasites.

Pathogenesis

Detrimental effects are usually difficult to attribute directly to tapeworms. More implications of problems associated with *A. perfoliata* have been suggested than with the other two tapeworm species.

The normal site of attachment of *A. perfoliata* is around the ileocecal valve. Large numbers may directly or indirectly cause reduction of this opening. There may be ulceration, inflammation, and formation of a diphtheritic membrane where the parasites are attached (Figures 3 and 4). Various other pathologic effects reported are perforation, intussusception (prolapse) of the terminal ileum (Figures 5 and 6) and cecum, and hypertrophy/hyperplasia (thickening) of the ileal walls (Figure 7). These effects seem to be more prevalent in weanling, yearling, and adolescent Thoroughbreds which have been studied more than other breeds. Intussusception of the small intestine and cecum can be corrected surgically and prognosis is good if done promptly. Clinical signs for which *A. perfoliata* should be considered as a possible cause are colic, poor growth, and unthriftiness. *Anoplocephala magna* (Figure 8) have been associated with enteritis.

Control

Treatment for tapeworms is a dilemma at this time because no drugs are labeled for their removal. However, pyrantel pamoate, on the market for removal of nematodes, has activity on *A. perfoliata*. This drug is commonly used because of its activity against *A. perfoliata*. At the therapeutic dose rate (6.6 mg base/kg), it is somewhat less active than the double dose rate (13.2 mg base/kg). Even though a 20X margin of safety of the 6.6 mg base/kg dose rate has been established, safety of higher dose rates has not been defined in breeding animals. Therefore, use of higher than the therapeutic dose rate of pyrantel pamoate is not recommended, particularly in pregnant animals. Limited data indicate at least some activity of the low dose rate (2.64 mg/kg) of pyrantel tartrate on *A. perfoliata*.

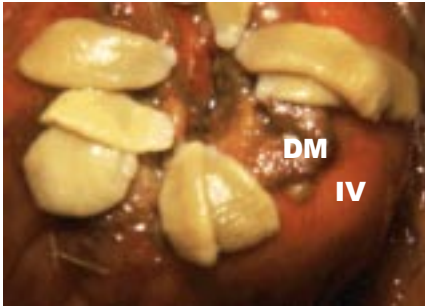

Figure 3. *Anoplocephala perfoliata*. Specimens located around the lumen of the ileo-cecal valve (IV) with a diphtheritic membrane (DM) present at the site of attachment.

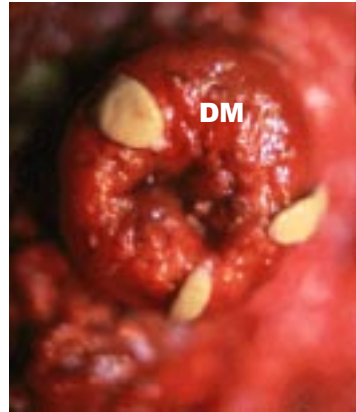

Figure 4. *Anoplocephala perfoliata*. Similar to Figure 3 but from another horse.

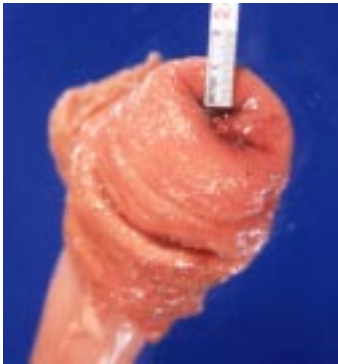

Figure 5. *Anoplocephala perfoliata* (not shown). Intussusception (prolapse) of the ileum.

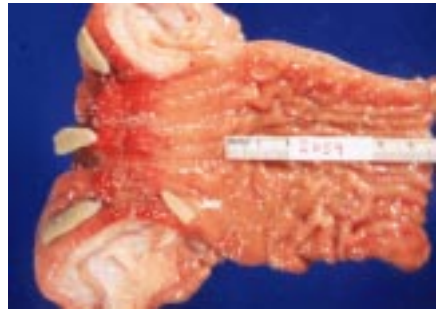


Figure 6. *Anoplocephala perfoliata*. Same as Figure 5 but area of intussusception opened with tapeworms evident.

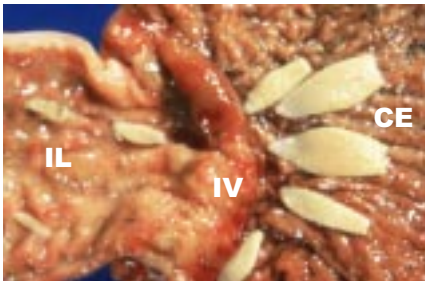

Figure 7. *Anoplocephala perfoliata*. Hypertrophy/hyperplasia (thickening) of the wall of the ileum (IL) with obvious specimens in the ileum and cecum (CE) around the ileo-cecal valve (IV).

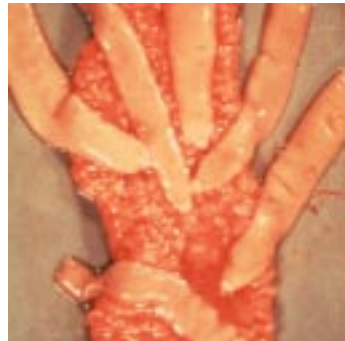

Figure 8. *Anoplocephala magna*. Specimens in the small intestine.

Educational programs of the Kentucky Cooperative Extension Service serve all people regardless of race, color, age, sex, religion, disability, or national origin. Issued in furtherance of Cooperative Extension work, Acts of May 8 and June 30, 1914, in cooperation with the U.S. Department of Agriculture, C. Oran Little, Director of Cooperative Extension Service, University of Kentucky College of Agriculture, Lexington, and Kentucky State University, Frankfort. Copyright © 1997 for materials developed by the University of Kentucky Cooperative Extension Service. This publication may be reproduced in portions or its entirety for educational or non-profit purposes only. Permitted users shall give credit to the author(s) and include this copyright notice. Issued 11-97, 5000 copies